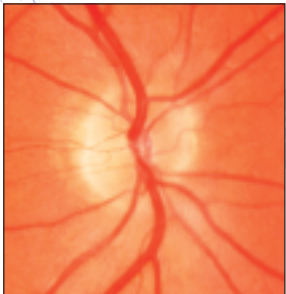
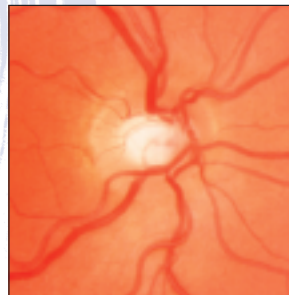
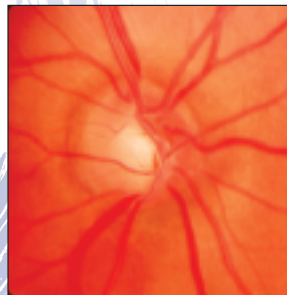
PROGRESSION OF OPTIC NERVE CUPPING



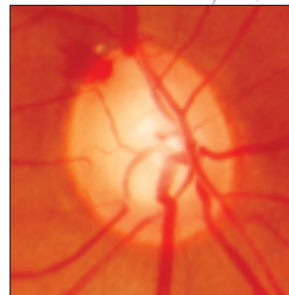
0.1 Cup-to-disc ratio
Normal optic nerve without cupping
Disc margins are sharp
Neural rim is intact 1



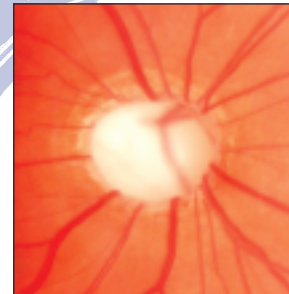
0.4 Cup-to-disc ratio
Early glaucoma
Neural rim is intact 4



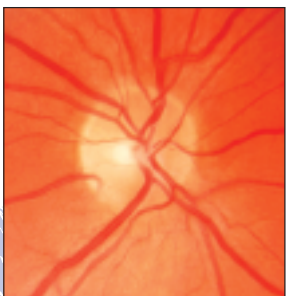0.6 Cup-to-disc ratio
Glaucoma with moderate cupping
Notch defect at 6:30 where neural rim is absent (Superior visual field defect corresponds) 6



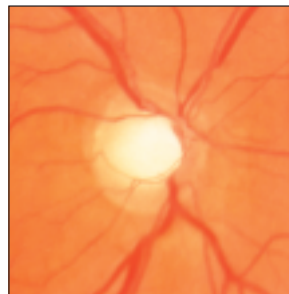0.8 Cup-to-disc ratio
Glaucoma with advanced cupping
Neural rim absent at 12:00
Disc hemorrhage at 11:00 8



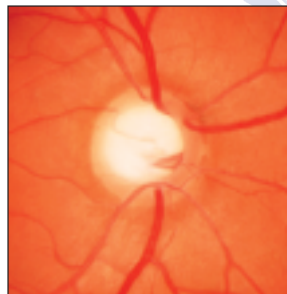
0.95 Cup-to-disc ratio
Glaucoma with severe cupping
Almost total cup
Neural rim very thin, but present 10



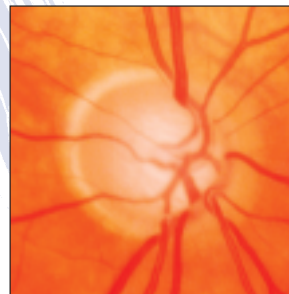
0.2 Cup-to-disc ratio
Normal optic nerve with small cup 2



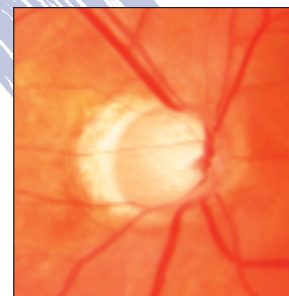
0.6 Cup-to-disc ratio
Glaucoma with moderate cupping
Neural rim is intact 5



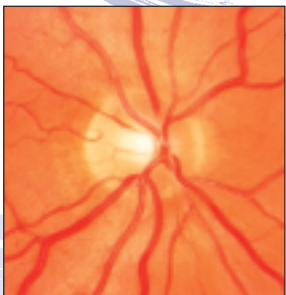0.7 Cup-to-disc ratio
Glaucoma with advanced cupping
Neural rim is thin 7



0.9 Cup-to-disc ratio
Glaucoma with advanced cupping and myopia
Sloped loss of temporal neural rim 9



0.95 Cup-to-disc ratio
Glaucoma with severe cupping
Almost total cup
Neural rim absent at 6:00
Very thin at 12:00 11

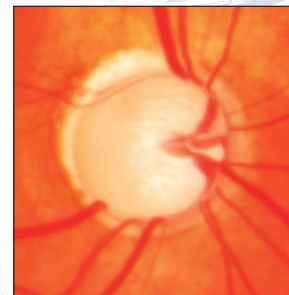

0.3 Cup-to-disc ratio
Normal optic nerve with slightly larger (than #2) cup 3

GLAUCOMA CENTER OF MICHIGAN

Excellence in the diagnosis and treatment of Glaucoma.

Southfield ♦ St. Clair Shores ♦ Dearborn



1.0 Cup-to-disc ratio
Glaucoma with total cupping
Neural rim absent
Fixation has been lost! 12